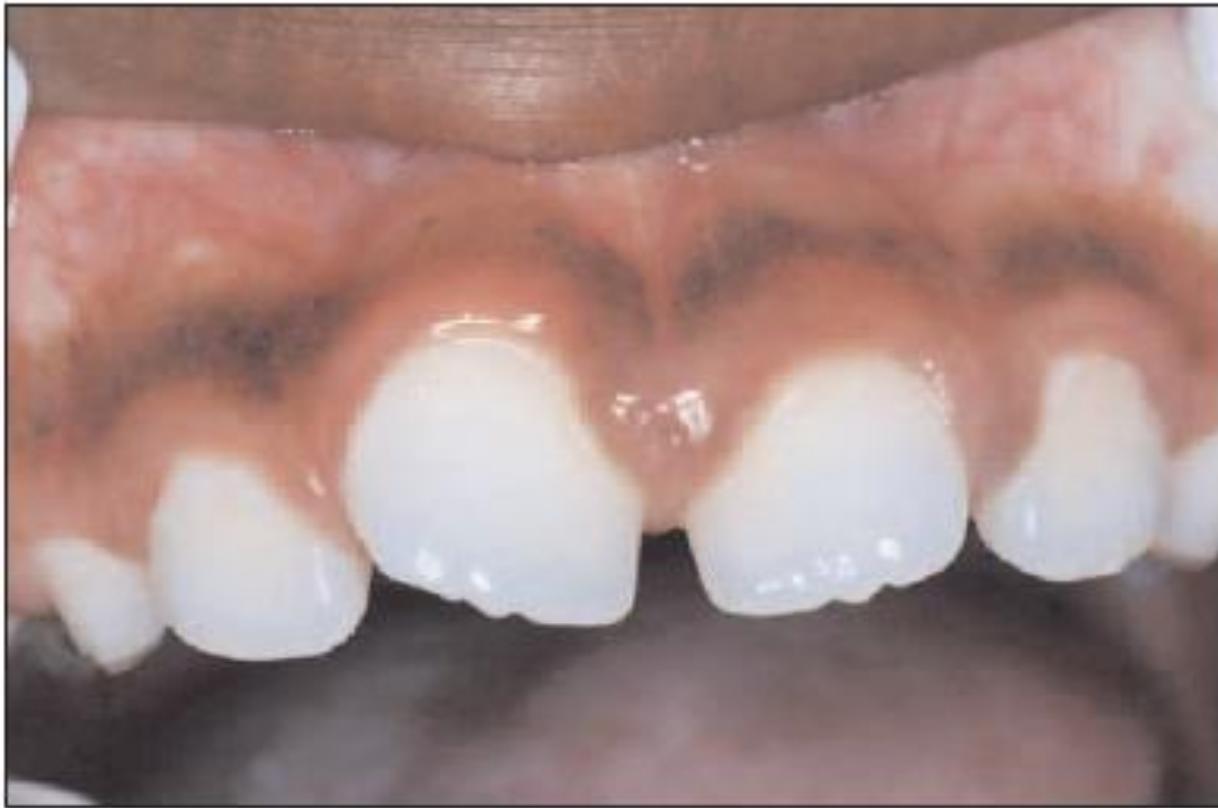

**Sample test of oral  
medicine fifth year 2020**

# Sample Questions

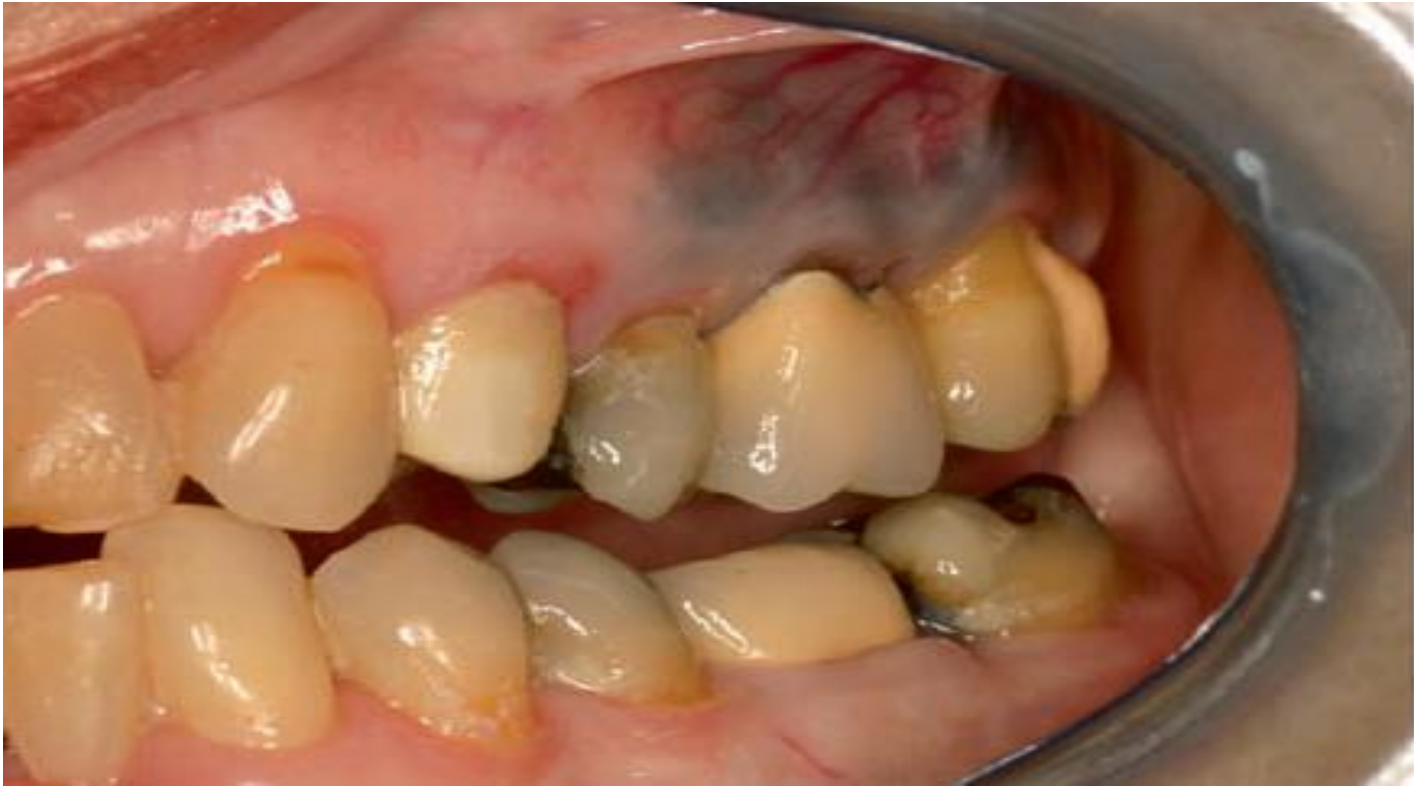# Identify



**This type of pigmentation is common in dark skinned persons often have pink mucosa with widespread diffuse macular fields of brown, gray, or even black pigmentation, with no evidence of any disease.**

- A. Peutz-Jeghers syndrome.**
- B. Addison's disease.**
- C. Melanoma.**
- D. Physiologic pigmentation.**

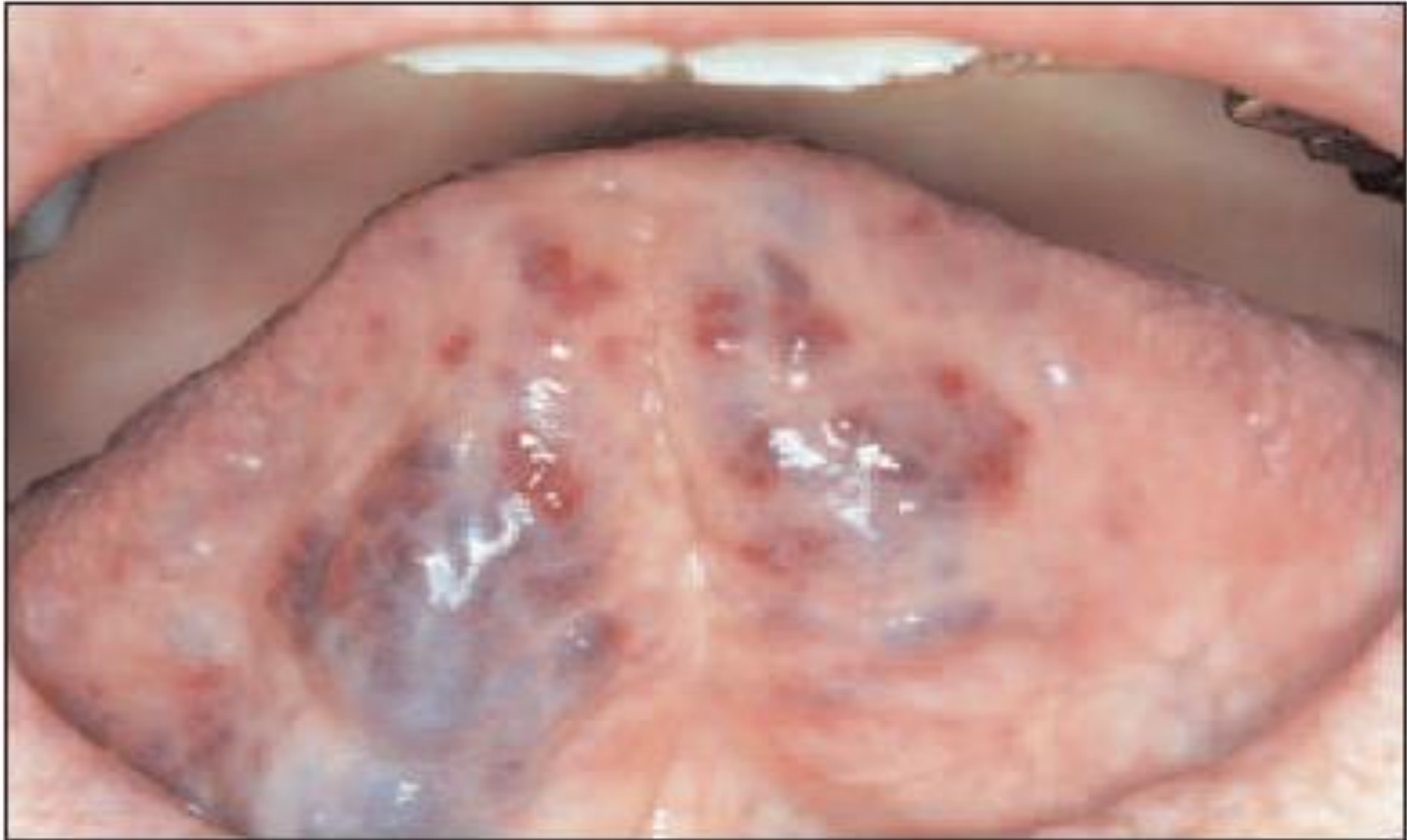
# Identify



This is a common oral disorder which occurs due to implantation of dental amalgam into the oral mucosa.

- A. Nevus.
- B. Melanoma.
- C. Normal physiologic pigmentation.
- D. Amalgam tattoo.

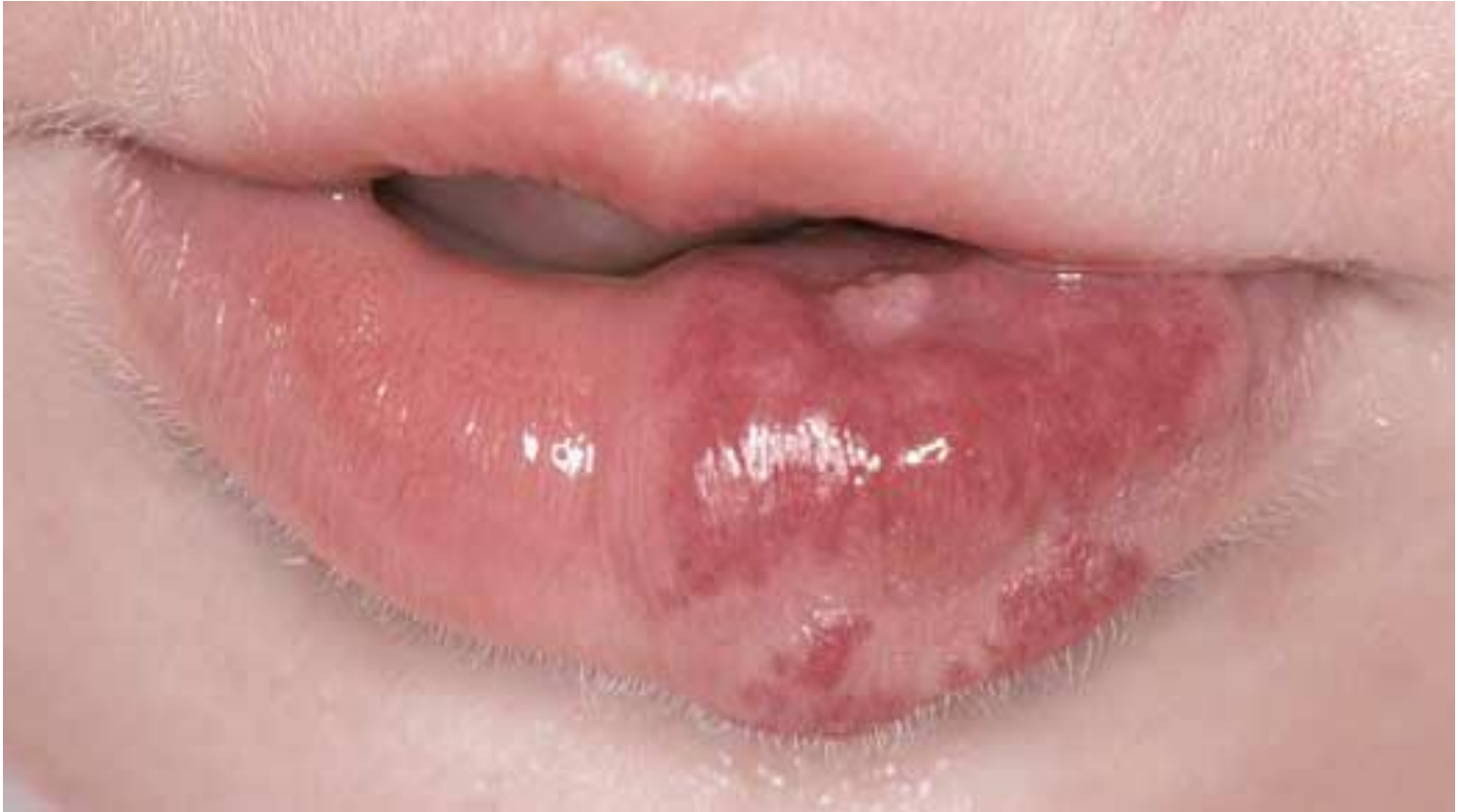# Identify



This is a case of pathologic dilations of veins and venules. It become more pronounced with age. The dilated vessels were soft to palpation and blanched on pressure.

- A. Kaposi sarcoma.
- B. Varices.
- C. Physiologic pigmentation.
- D. Smoker's melanosis.

# Identify



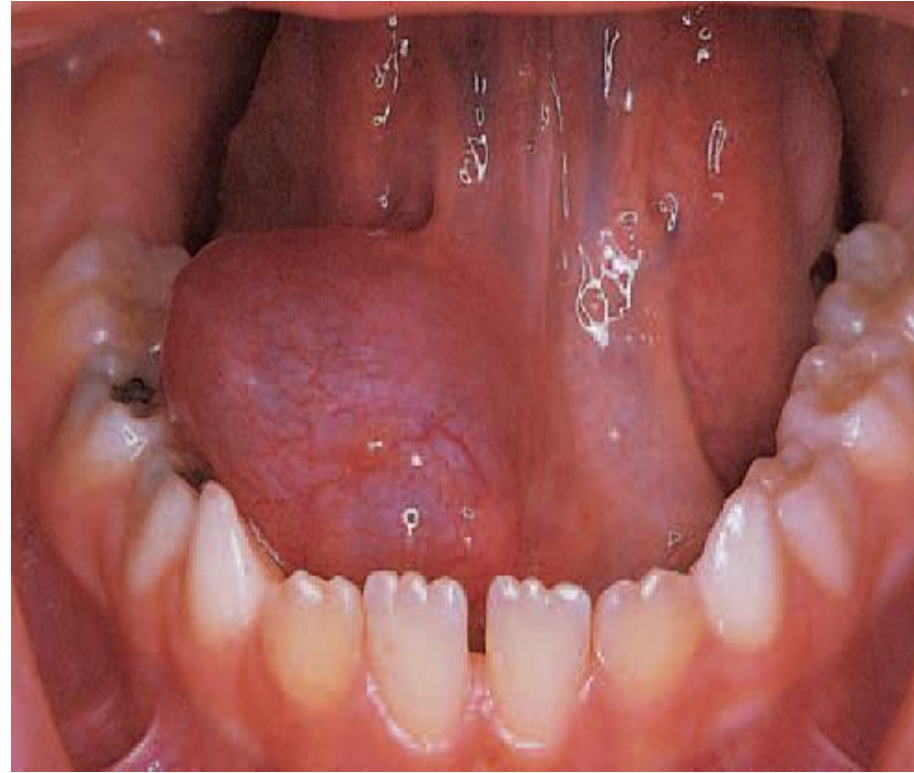
**This is a developmental abnormality of blood vessels. It is usually noted initially in infancy or childhood and regress after puberty. Diascopy of the lesions usually produces blanching.**

- A. Purpura.**
- B. Melanoma.**
- C. Ecchymosis.**
- D. Hemangioma**

# Identify

**This is a large bluish, translucent swelling in the floor of the mouth caused by a mucous extravasation or retention cyst.**

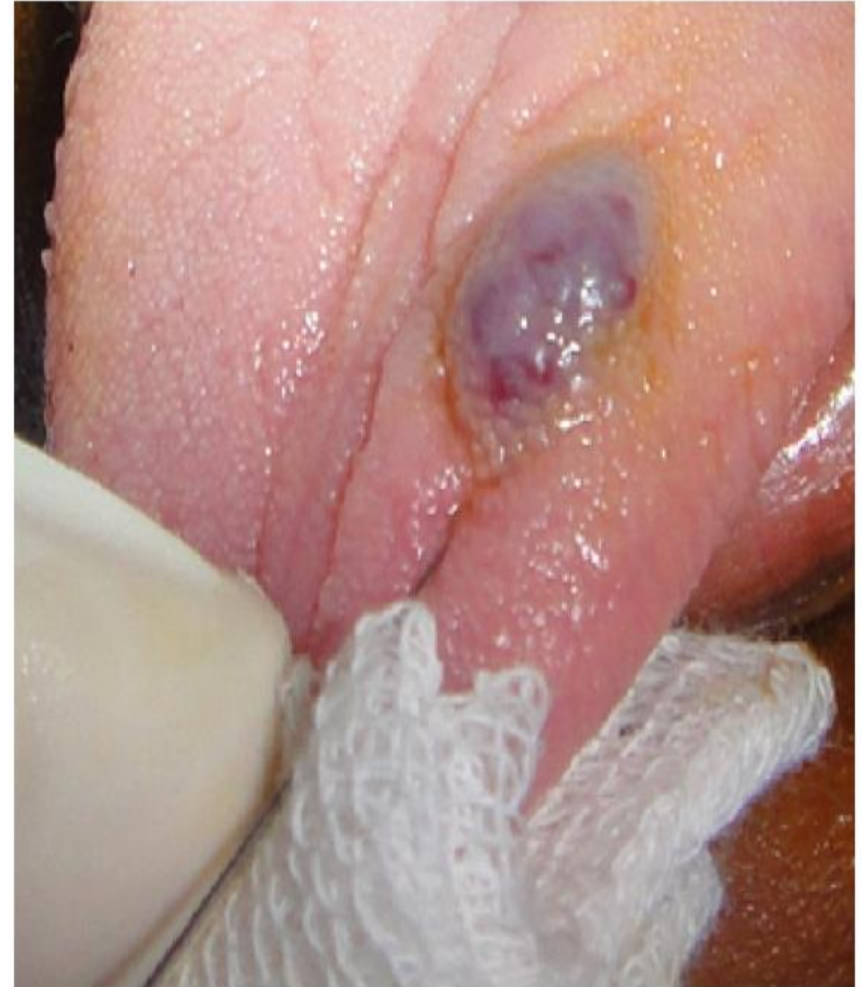- A. ranula**
- B. mucocele**
- C. lymphoma**
- D. epithelioma**



# Identify

**A blue nodular mass on the lateral border of the tongue that is soft, smooth and blanches upon pressure. It is most likely to be:**

- A. Lymphoma**
- B. Hemangioma**
- C. Epulis Fissuratum**
- D. Epithelioma**

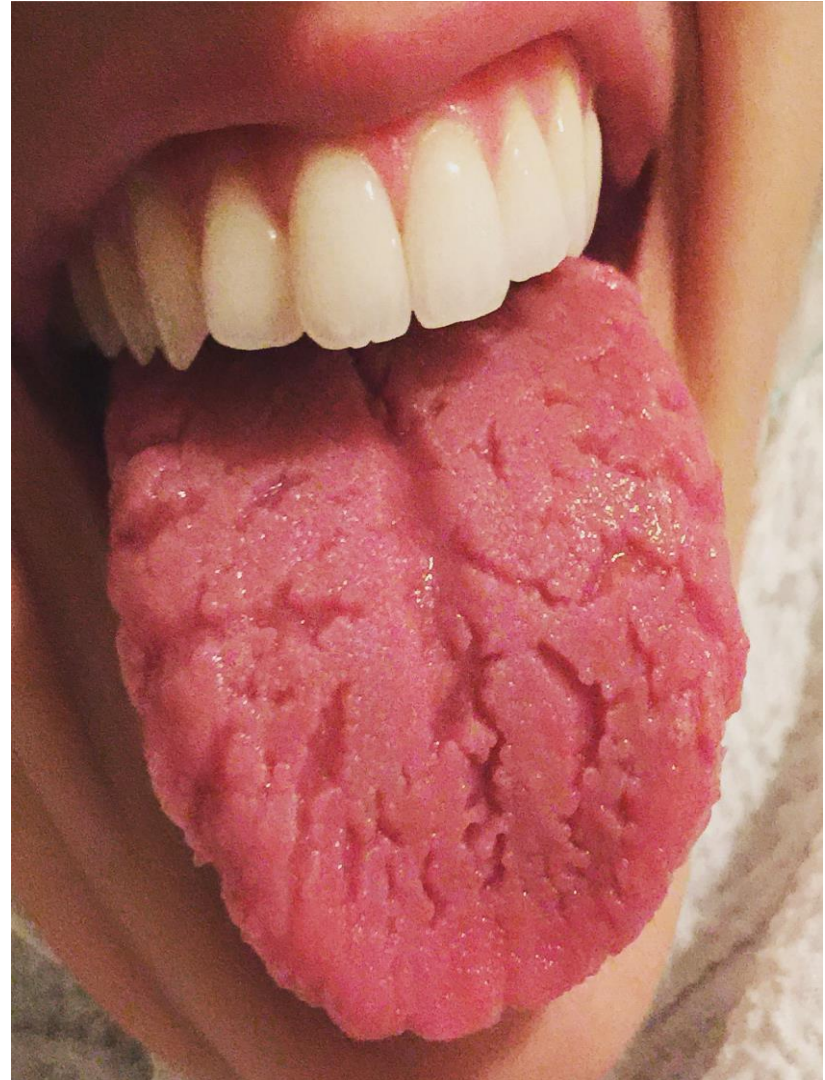




# Identify

**A benign condition characterized by deep grooves in the dorsum of the tongue. Although these grooves may look unsettling, the condition is usually painless. Some individuals may complain of an associated burning sensation.**

- A. Hairy tongue**
- B. Scrotal tongue**
- C. Geographic tongue**
- D. Bifid tongue**



**Name this eye**

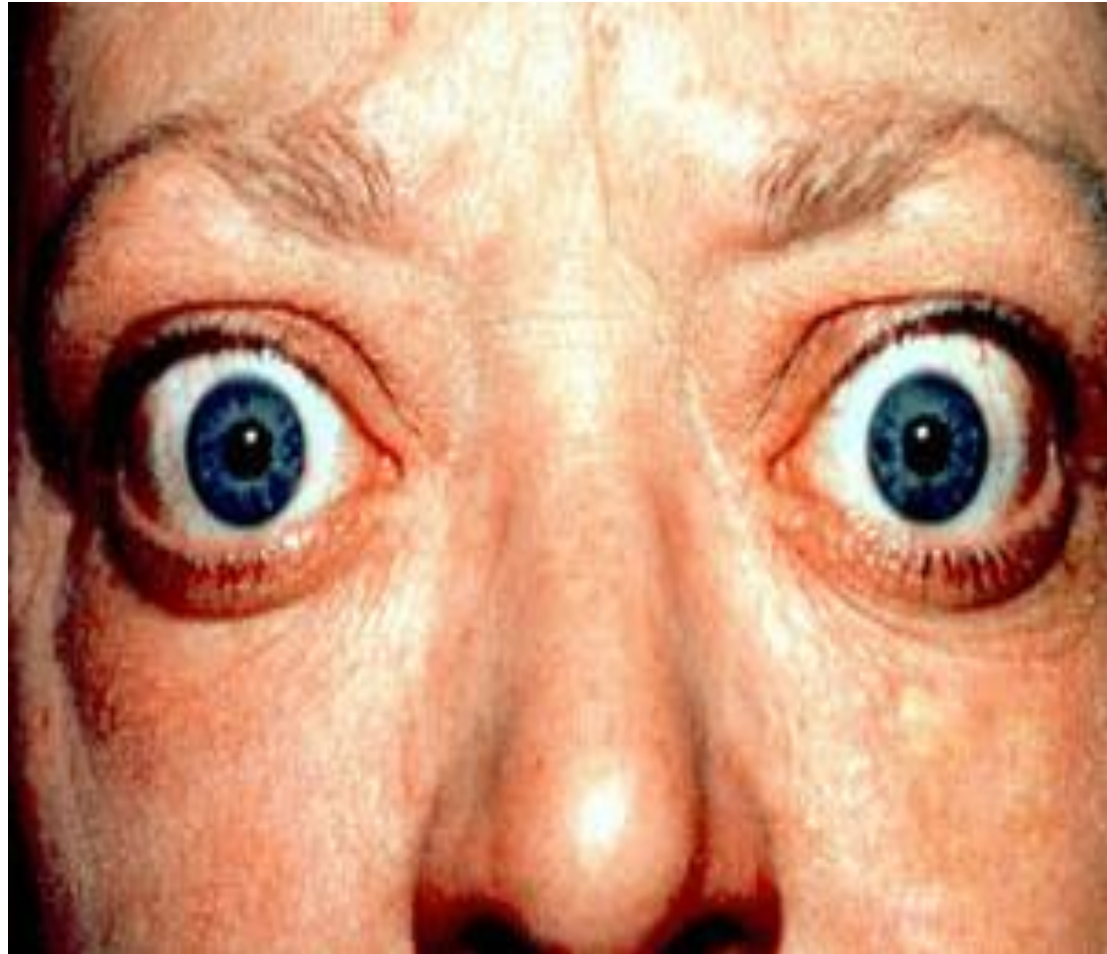**phenomenon**

**A. Hyperterolism**

**B. Exophthalmia**

**C. Enophthalmia**

**D. xerophthalmia**



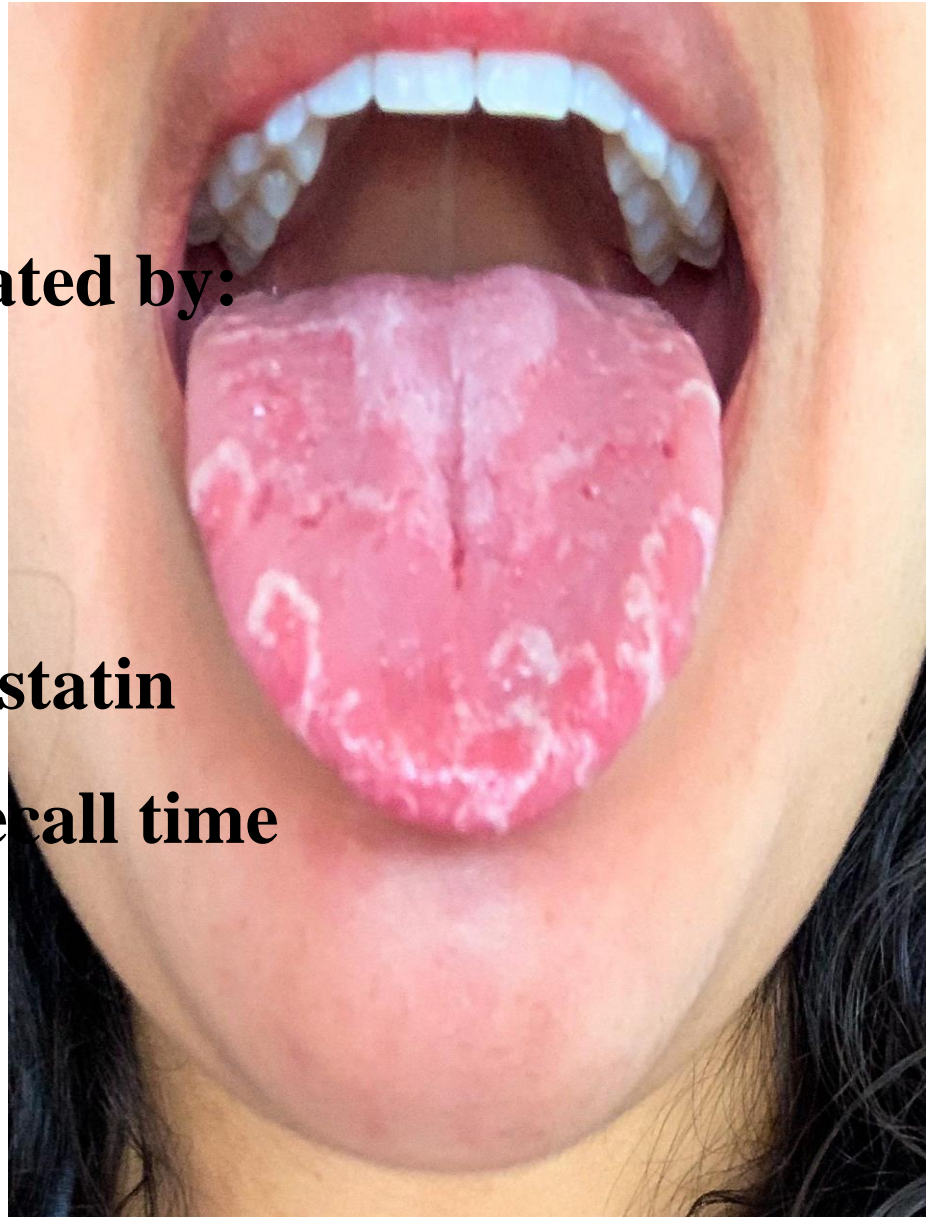**This condition should be treated by:**

**A. Excision of the lesion**

**B. Penicillin therapy**

**C. Topical application of Nystatin**

**D. Routine observation at recall time**



## Practical Exam Topics

Pigmented lesions of the oral cavity.

Tongue diseases.

Salivary gland diseases.

Disorders of Pituitary gland.

Disorders of thyroid gland.

Disorders of parathyroid gland.

Cervicofacial lymphadenopathy.

Etiological classification of lymphadenopathy.